Chapter-10

Skeletal muscles

- Histology
- Physiology of muscle contraction
- Disorder of skeletal muscles

Histology of Muscles

The scientific study of muscles is known as myology. The primary function of muscle—the transformation of chemical energy into mechanical energy to generate force, perform work, and produce movement. In addition, muscle tissues stabilize body position, regulate organ volume, generate heat, and propel fluids and food matter through various body systems.

Properties of muscles—

- Electrical excitability.
- Contractility.
- Extensibility.
- Elasticity.

Classification of muscular tissue—

a. Depending upon striations.
   - Striated muscle. Example- skeletal muscle and cardiac muscle.
   - Non-striated muscle. Example- smooth muscle.

b. Depending upon control.
   - Voluntary control. Example- skeletal muscle.
   - Involuntary control. Example- cardiac muscle and smooth muscle.

c. Depending upon situation.
   - Skeletal muscle.
   - Cardiac muscle.

- Smooth muscle.

Features of skeletal, cardiac, and smooth muscle fibres.

Features	Skeletal muscle	Cardiac muscle	Smooth muscle
Location	Associated with bone	In the heart	In the visceral organs
Shape	Cylindrical and unbranched	Branched	Spindle- shaped
Number of nucleus	More than one	One	One
Striations	Present	Present	Absent
Action	Voluntary action	Involuntary action	Involuntary action
Control	Only neurogenic	Myogenic	Both
Structure		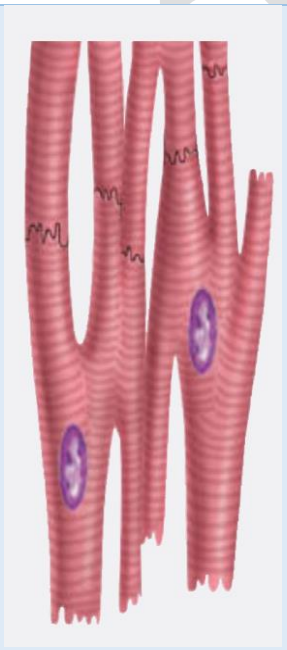	

Skeletal muscle.

Skeletal muscle is situated in associated with bones forming the skeletal system. It forms about the 40% to 50% of body mass. It is a type of voluntary and striated muscle. These muscles are supplied by somatic nerves.

Structure of skeletal muscle—

Muscle mass or muscle tissue is made up of a large number of individual muscle cells or myocytes. The muscle cells are commonly called muscle fibres because these cells are long and slender in appearance. Skeletal muscle fibres are multinucleated and are arranged parallel to one another with some connective tissue in between.

- Muscle mass is separated by the fibrous tissue layer known as fascia, beneath the fascia muscle is covered by a connective tissue sheath called epimysium.
- Muscle fibres are arranged in various groups called bundles or fasciculi, which is covered by connective tissue sheath called perimysium.
- And each muscle fibres are covered by a connective tissue layer called the endomysium.

Cell membrane of muscle fibres is called sarcolemma present beneath the endomysium. Cytoplasm of the muscle is known as sarcoplasm.

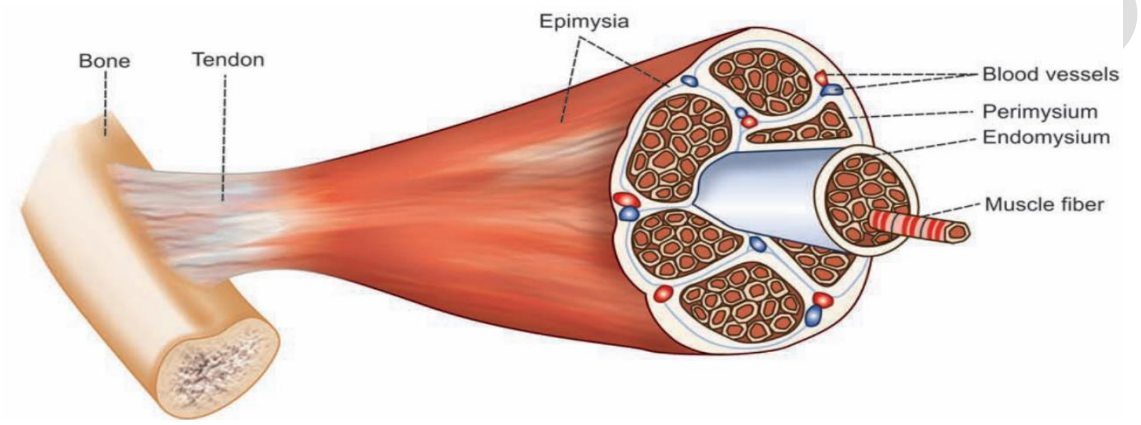

SKELETAL MUSCLE STRUCTURE

PHYSIOLOGY OF MUSCLE CONTRACTION—

1. **NEUROMUSCULAR JUNCTION—**

Junction between terminal branch of the nerve fibre and muscle fibre. Membrane of the nerve ending is called presynaptic membrane and membrane of the muscle fibre is called post synaptic membrane. Space between these two membranes is called synaptic cleft here acetylcholinesterase is present. Transformation mechanism of signal is occurring in many steps—

- Release of acetylcholine.
- Action of acetylcholine.
- Development of endplate potential.
- Destruction of acetylcholine.

2. **MUSCLE CONTRACTION—**

Structural and functional unit of the muscle contraction is Sarcomere.it is also called the basic contractile unit of the muscle. Relaxed sarcomere length is about 2 to 3 µ and it extends between two ‘Z’ lines of myofibril.

Each myofibril consists of an alternate dark 'A' band and light 'I' band. In middle of 'A' band, there is a light area called 'H' zone. In the middle of 'H' zone lies the middle part of myosin filament called as 'M' line. Myofilaments are of two types—

1. Actin filaments.
2. Myosin filaments.

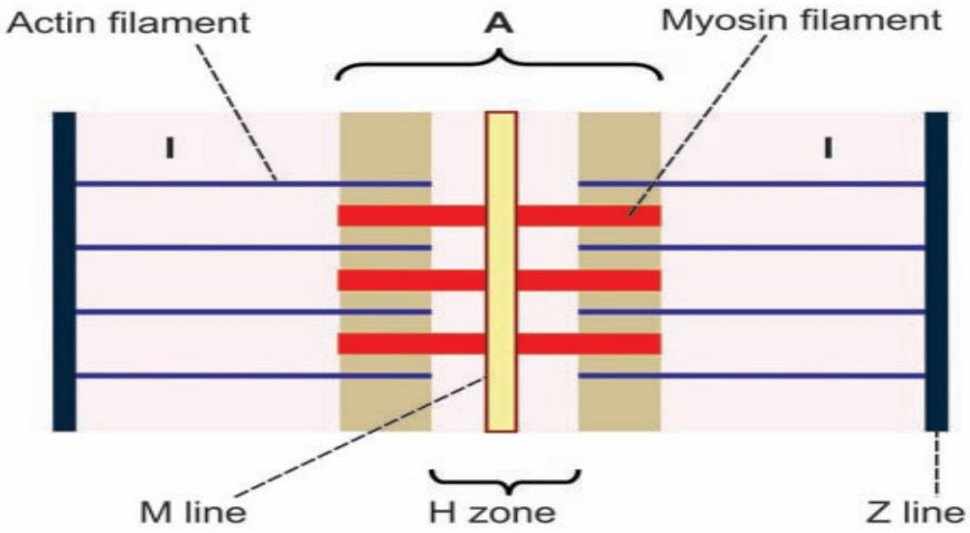

SARCOMERE A=A BAND I=IBAND.

1. Actin filament— Each actin filament consists of the 3 proteinous molecules.
   a. Actin molecule— Major constitutes of the actin filament. Each actin molecule is called F-actin and it is the polymer of a small protein known as G-actin. There are about 300 to 400 actin molecules in each actin filaments. Each F-actin molecule has an active site to which the myosin head is attached.
   b. Tropomyosin— It situated along the double helix strand of actin filament. In relaxed condition of the muscle, the tropomyosin molecules cover all the active sites of F-actin molecules.
   c. Troponin—it is formed by three subunits—
      - Troponin I, which is attached to F-actin.
      - Troponin T, which is attached to tropomyosin.
      - Troponin C, which is attached to calcium ions.
2. Myosin filament— Each myosin molecule has two portions-
   a. Tail portion— it is made up of two heavy chains, which twist around each other in the form of a double helix.

b. Head portion—myosin head has two attachment sites. One site is for actin filament and the other one is for one ATP molecule. Myosin head is absent in the central part of myosin filament that is

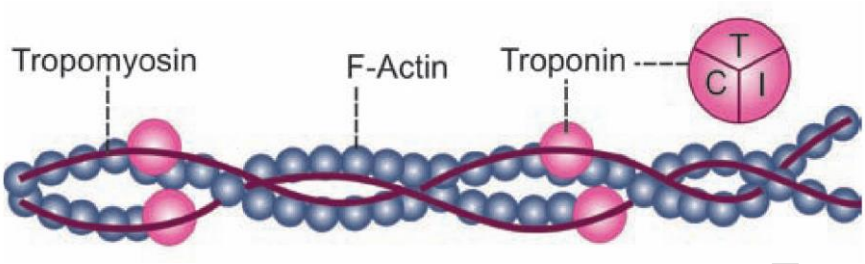

PART OF ACTIN FILAMENT TROPONIN SUBUNIT T, C, I.

in the 'H' zone.

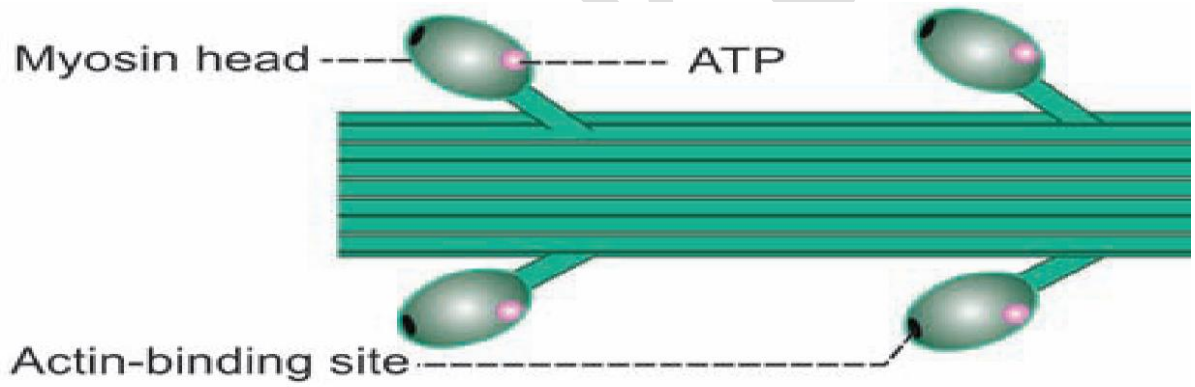

MYOSIN FILAMENT

MECHANISM OF MUSCLE CONTRACTION—

Mechanism of muscle contraction is best explained by sliding filament theory which states that contraction of a muscle fibre takes place by the sliding of the thin filament over the thick filament. Muscle contraction is initiated by a signal sent by the central nervous system via a motor neuron.

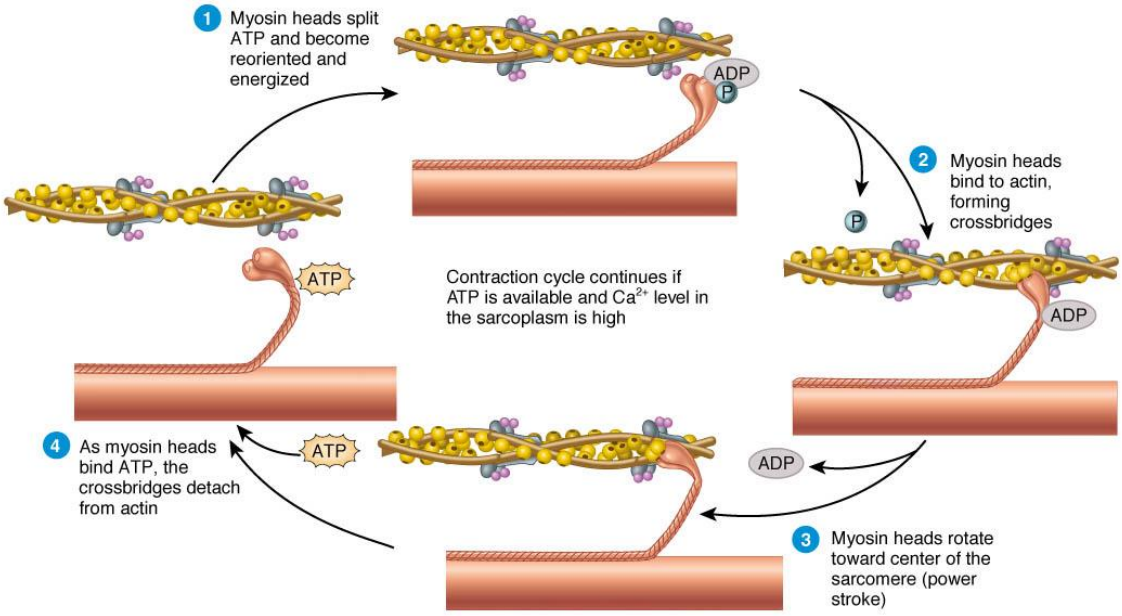

STAGES IN CROSS BRIDGE FORMATION, ROTATION OF HEAD AND BREAKING OF CROSS BRIDGE.

DISORDERS OF SKELETAL MUSCLES— common diseases of skeletal muscles are—

1. **Muscular dystrophy**— it is characterized by progressive degeneration of muscle fibres, without involvement of nervous system. Mostly it has hereditary origin.
2. **Myasthenia gravis**— It is an autoimmune disease caused by due to the development of autoantibodies (IgG autoantibodies) against the receptors of acetylcholine. It is characterized, to the inability of neuromuscular junction to transmit impulse from nerve to the muscle.
3. **Disease involving muscle tone**
    - **Hypertonia—** Hypertonia or hypertonicity is a muscular disease characterised by increased muscle tone and inability of the muscle to stretch.
    - **Hypotonia—** Hypotonia is the muscular disease characterised by decreased muscle tone. The tone of the muscle is decreased or lost. Muscle offers very little resistance to stretch.
    - **Myotonia—** Myotonia is a congenital disease characterized by continuous contraction of muscle and slow relaxation even after the cessation of voluntary act.

4. **Lambert-Eaton syndrome—** Lambert-Eaton syndrome is a disorder of neuromuscular junction caused by development of antibodies against calcium channel in the nerve terminal, resulting in reduction in the release of quanta of acetylcholine. This disease is commonly associated with carcinoma, so it also called as carcinomatous myopathy.
5. **Mitochondrial myopathy—** It is an inherited disease due to the defects in the mitochondria of muscle fibres.

Noteskarts